

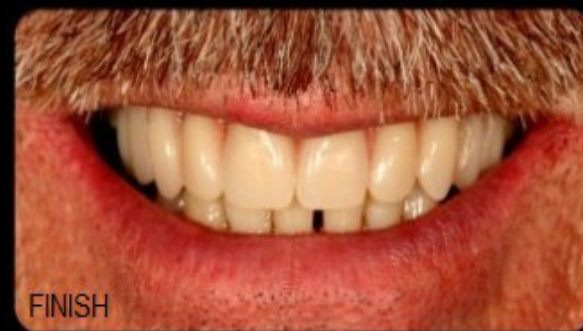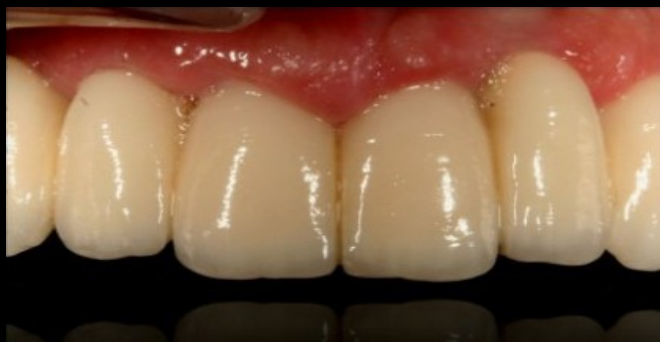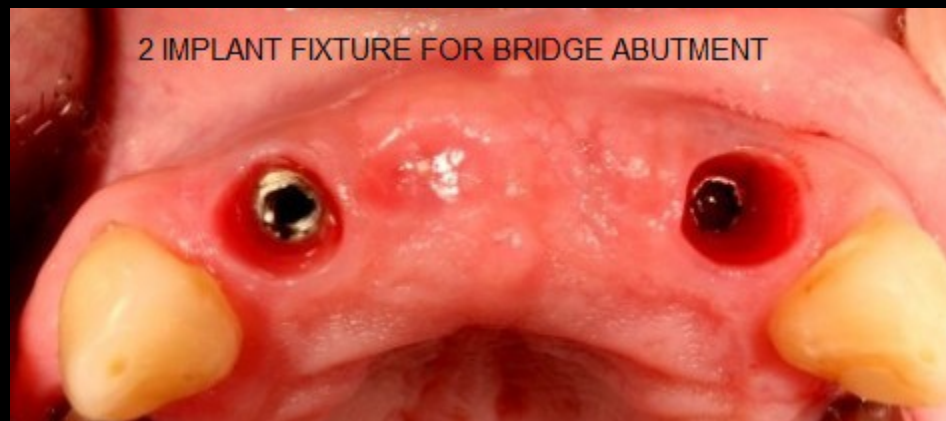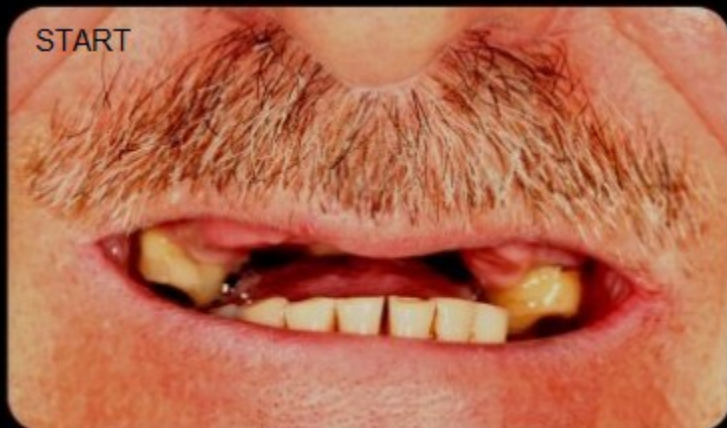
WELCOME



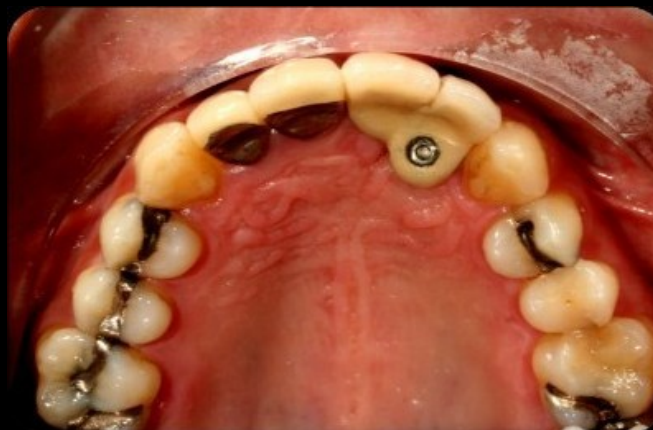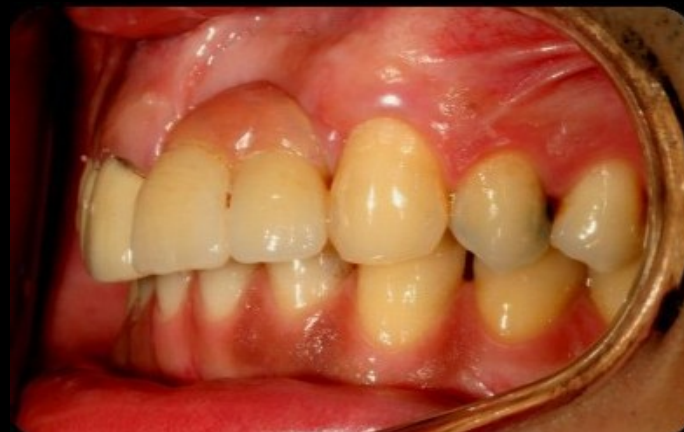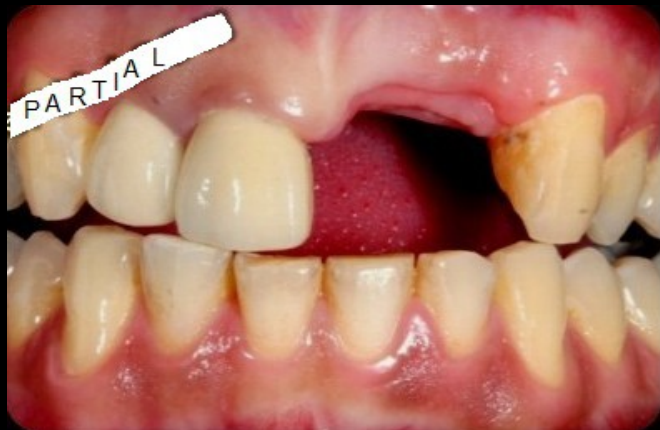ADVANCED DENTAL CARE & ORTHODONTIC



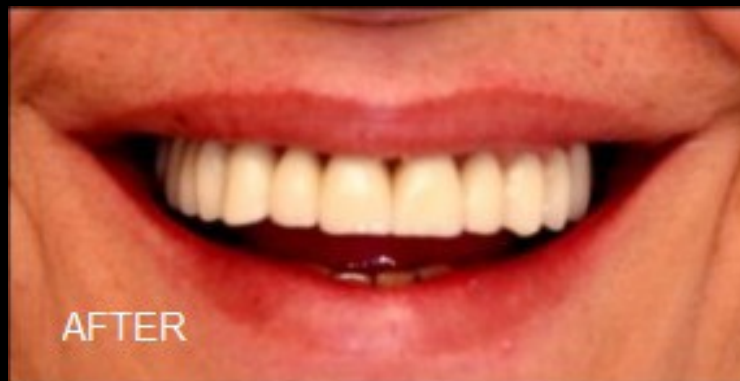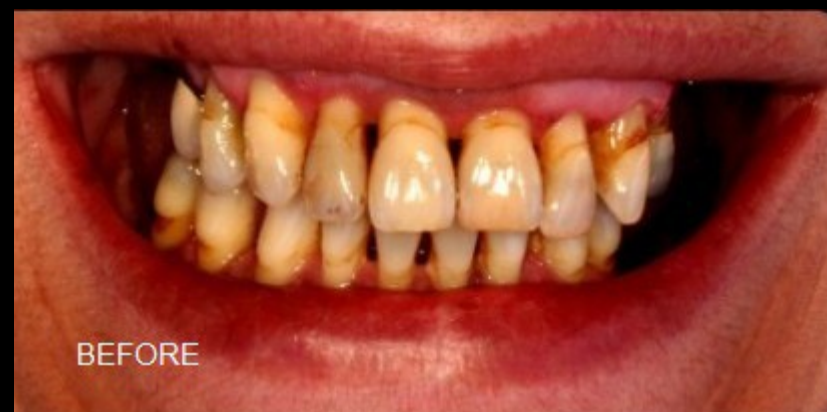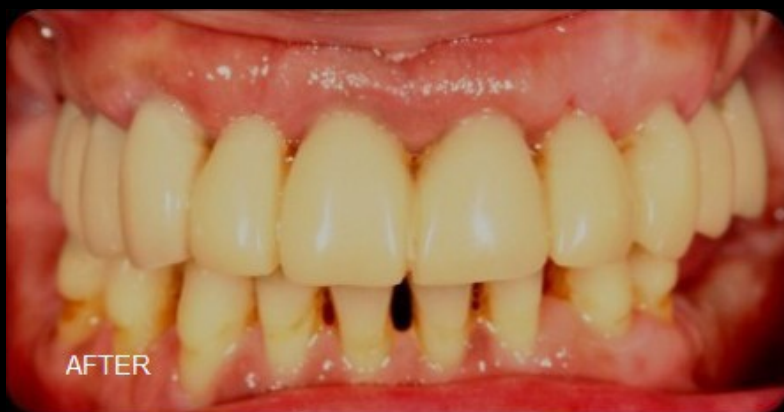IMPLANT FIXED PARTIAL DENTURE



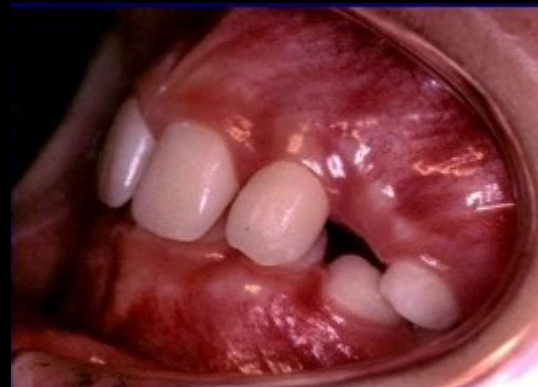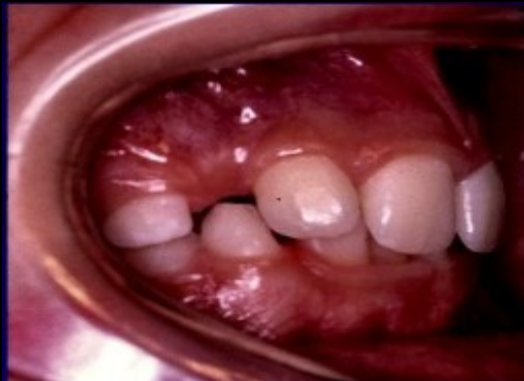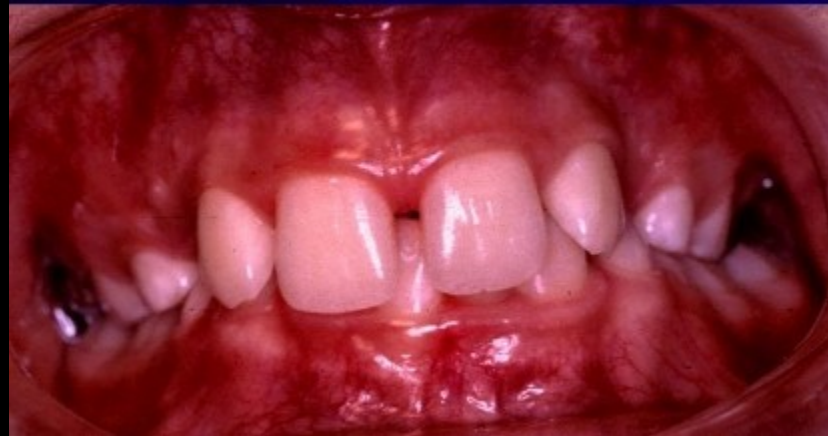IMPLANT SUPPORTING PARTIAL DENTURE



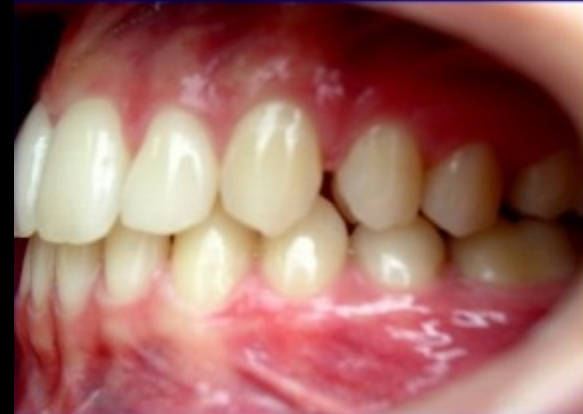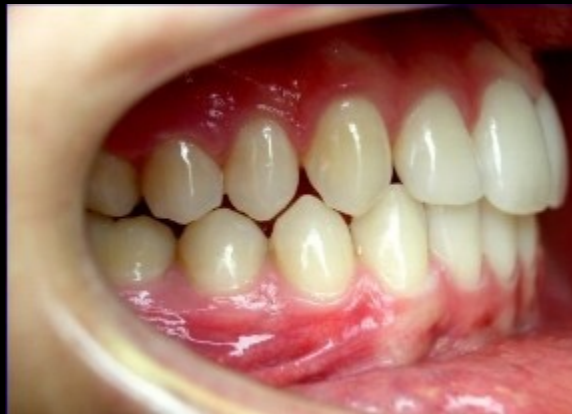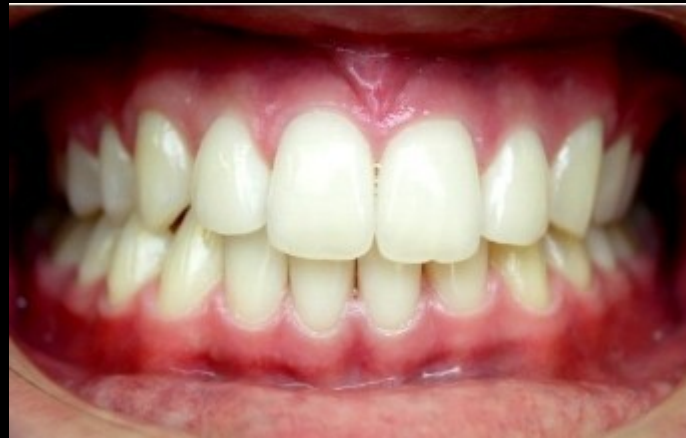UPPER ARCH REHABILITATION (IMPLANT)



**BEFORE ORTHODONTIC
(severe DEEP bite)**

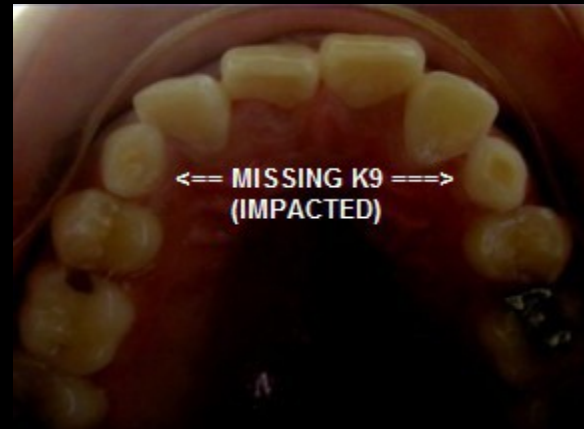
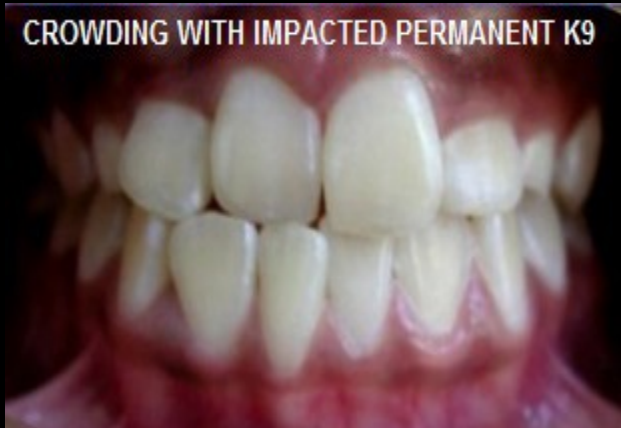
AFTER ORTHODONTIC

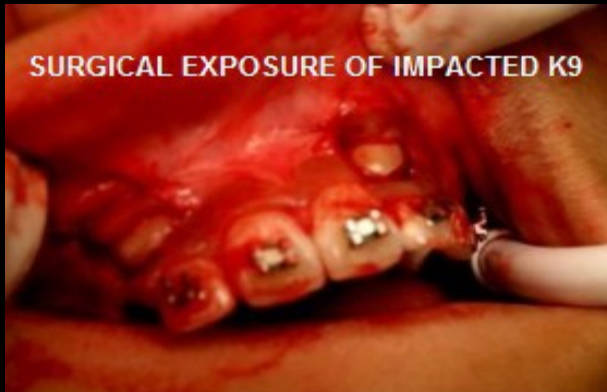

PERMANENT CUSPID IMPACTION

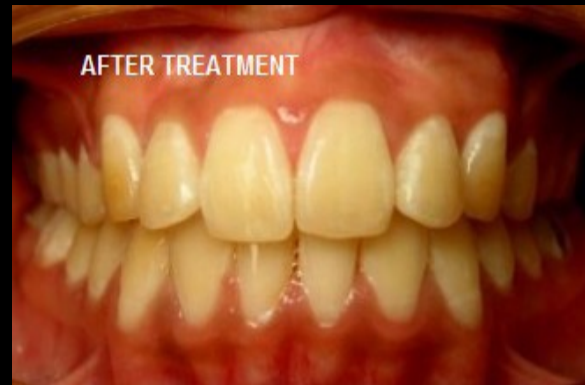CROWDING WITH IMPACTED PERMANENT K9



SURGICAL EXPOSURE OF IMPACTED K9

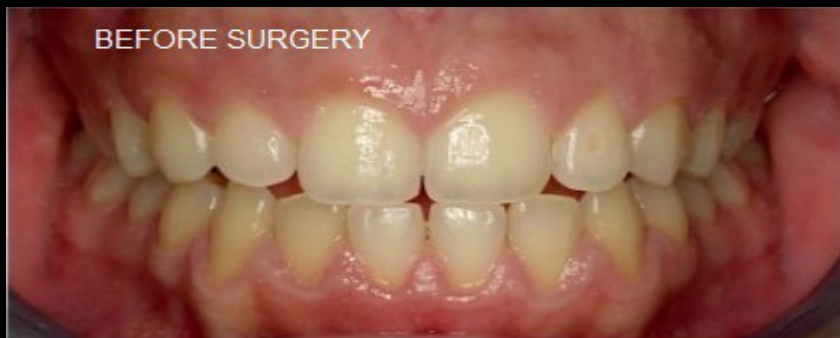

AFTER TREATMENT

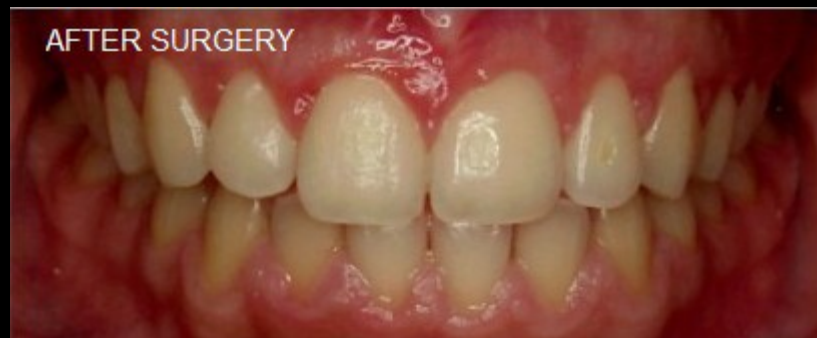

GUMMY SMILE CORRECTIVE SURGERY

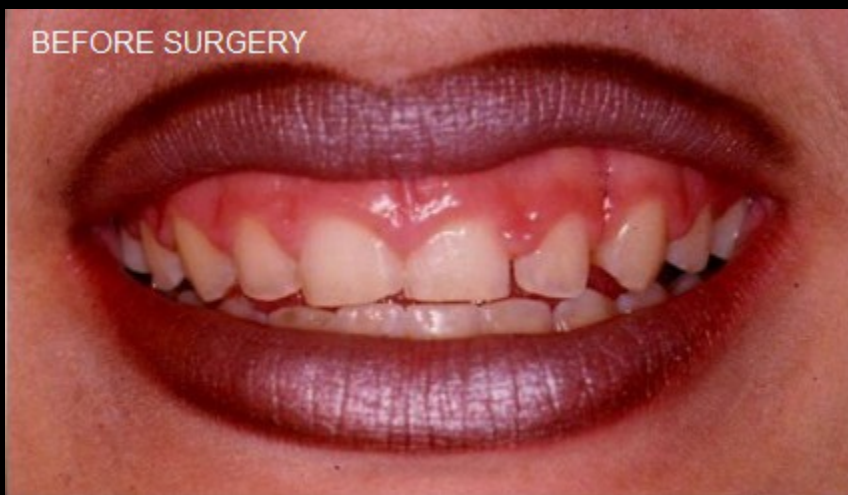BEFORE SURGERY



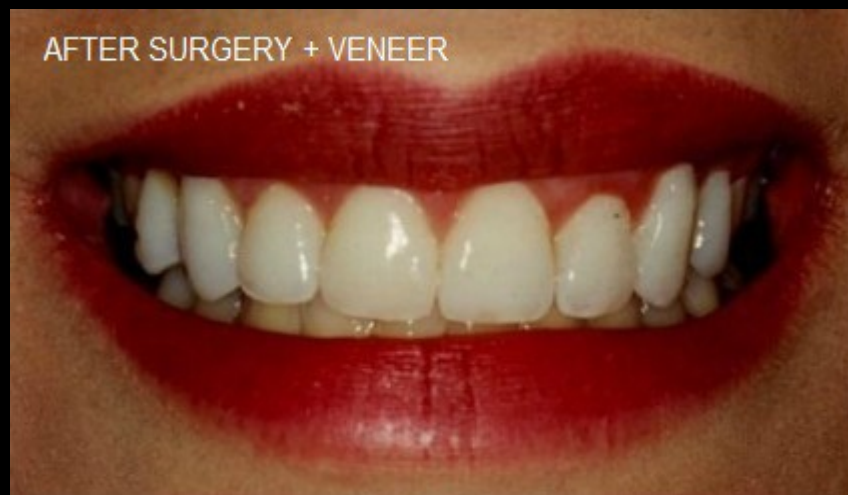AFTER SURGERY



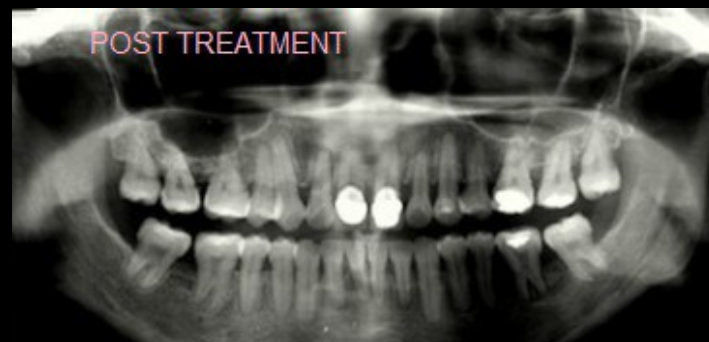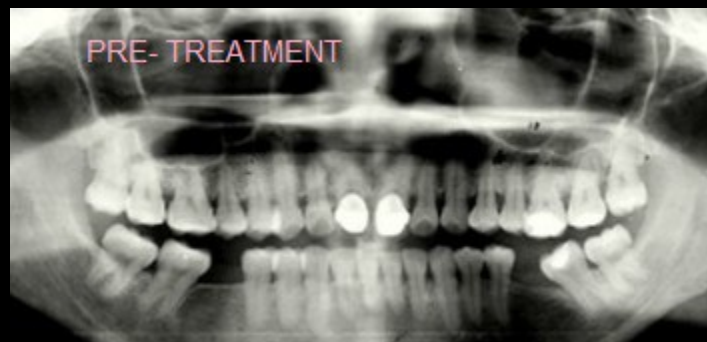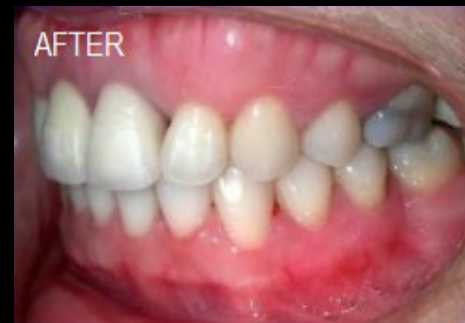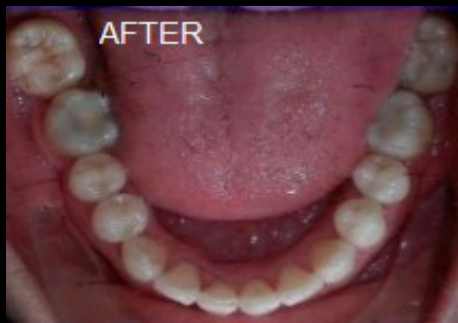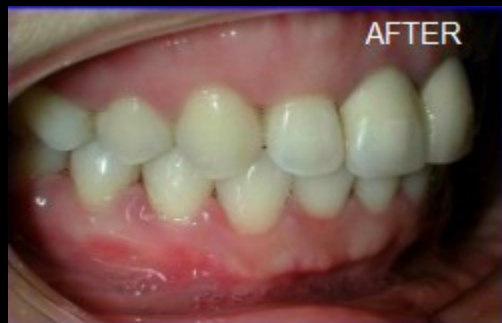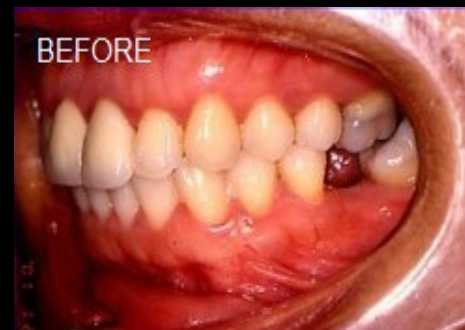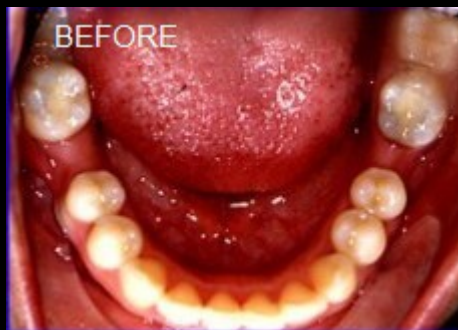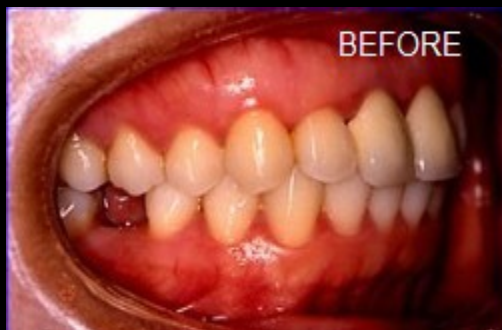BEFORE SURGERY



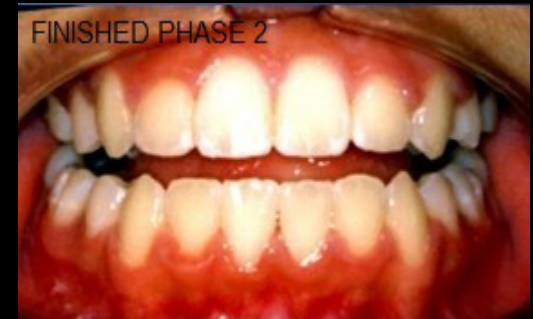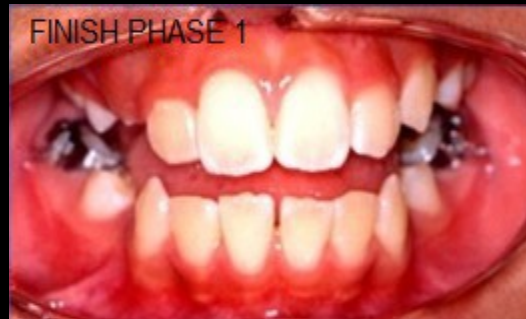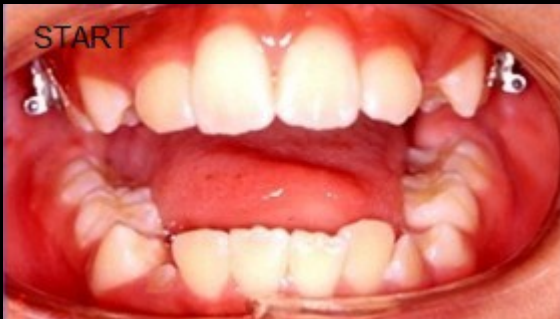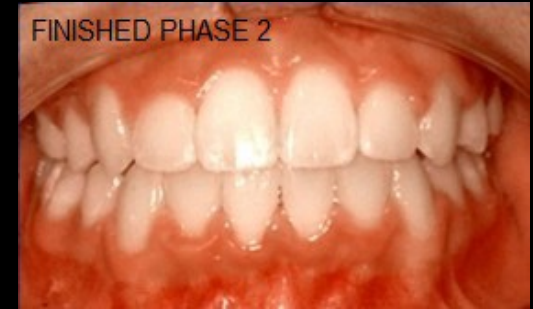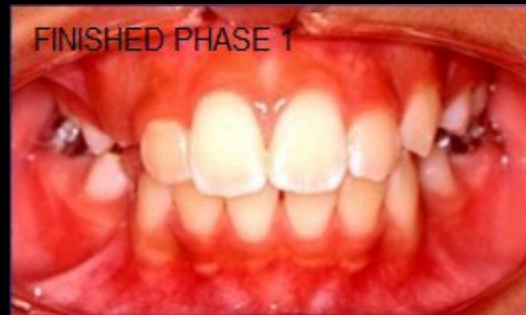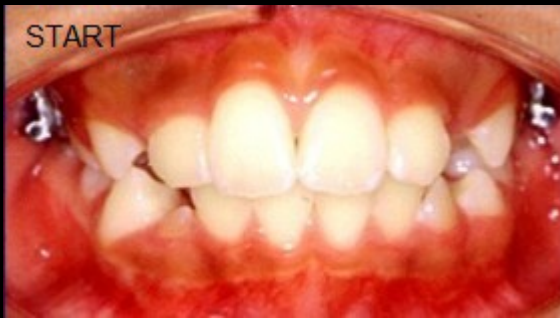AFTER SURGERY + VENEER



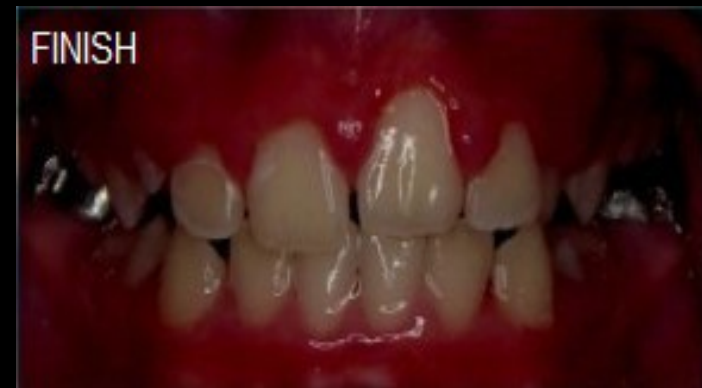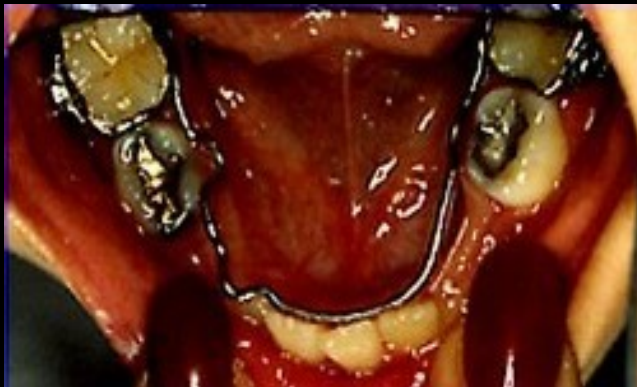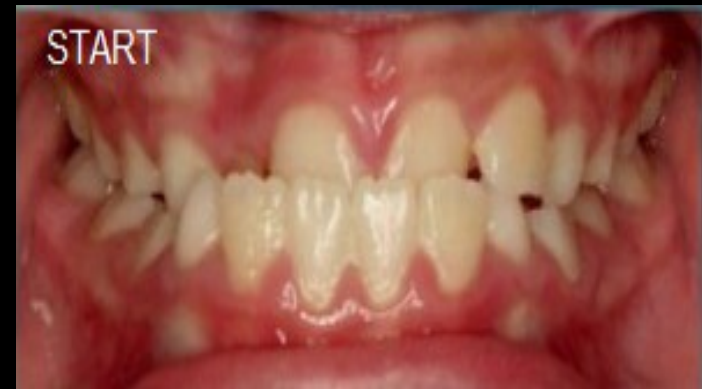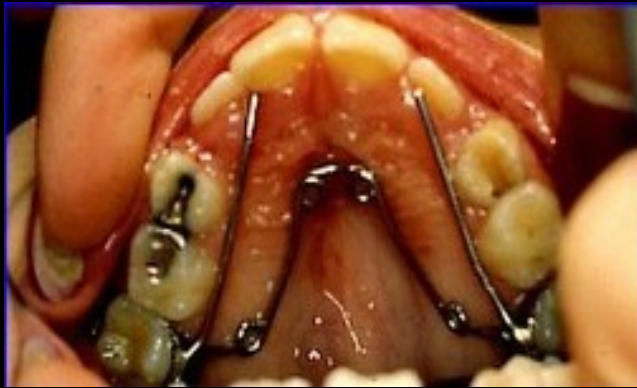MOLAR UPRIGHTING AND SPACE CLOSURE



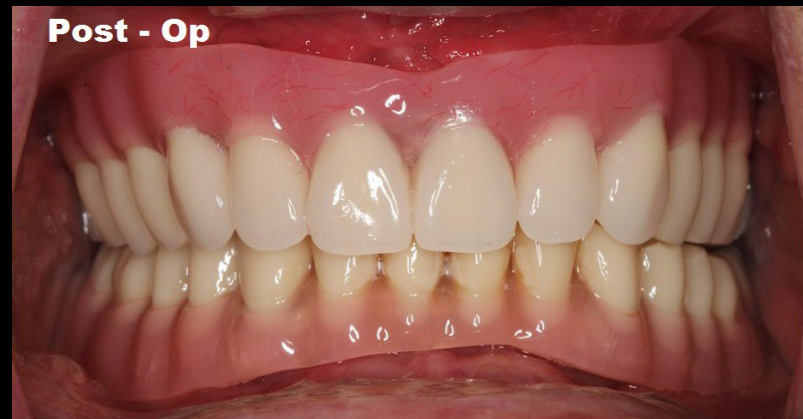
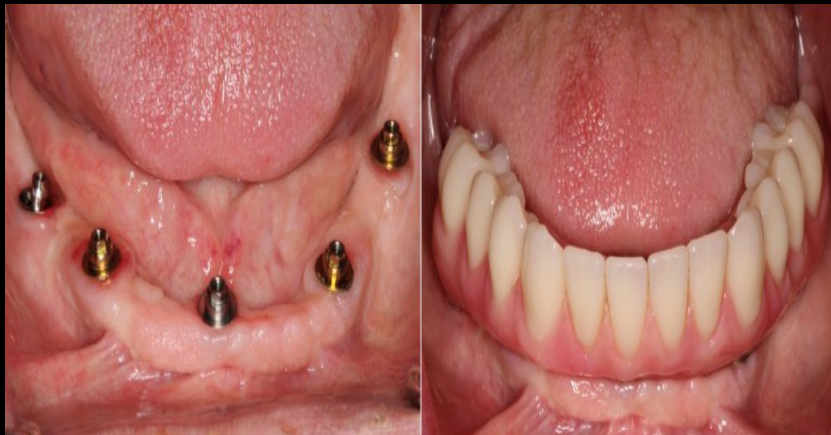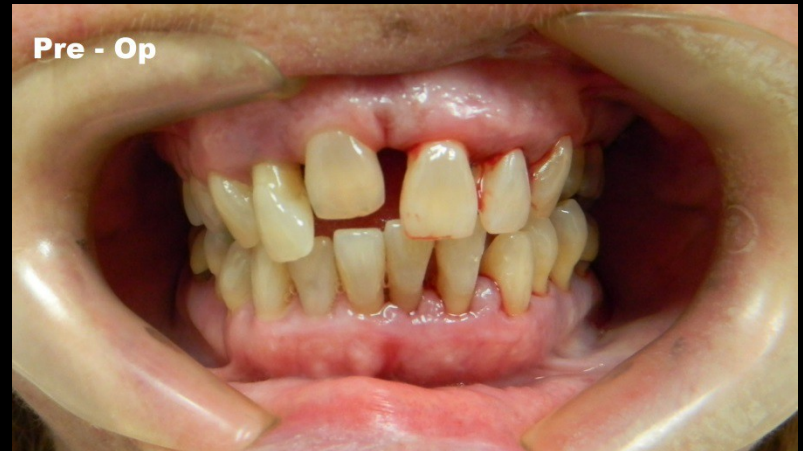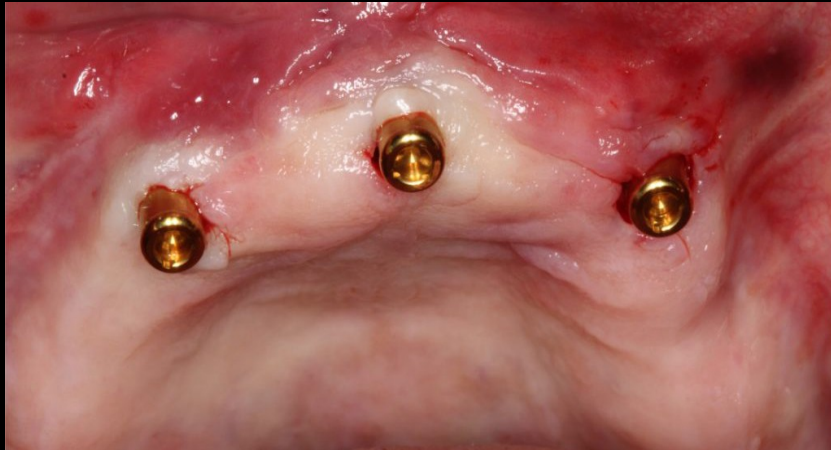PHASE 1&2 ORTHODONTIC



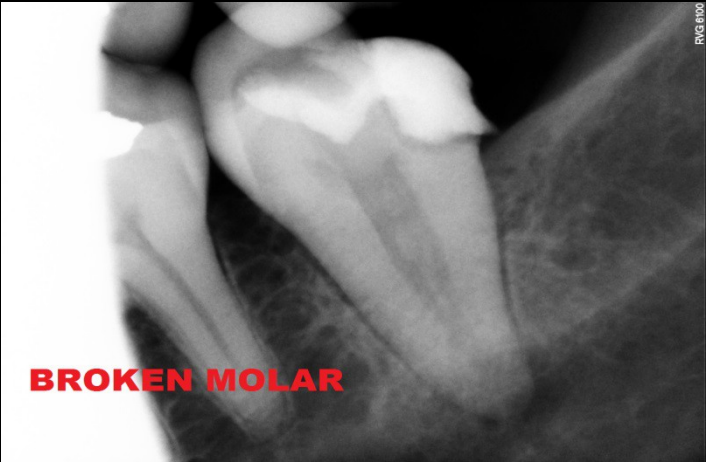
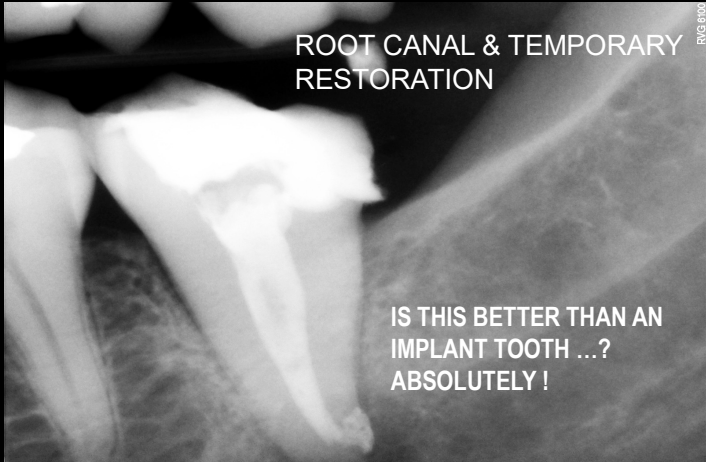
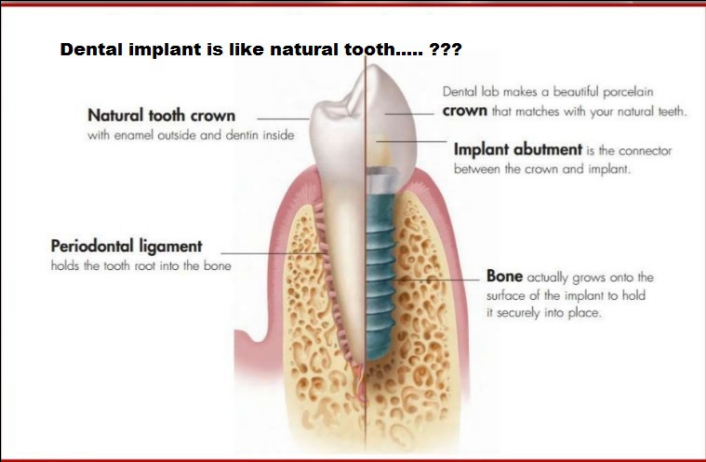
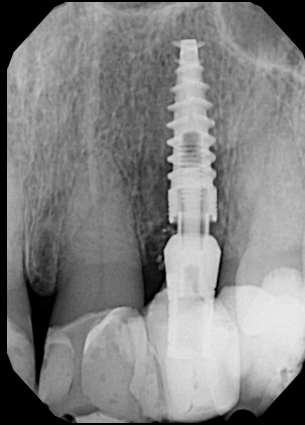
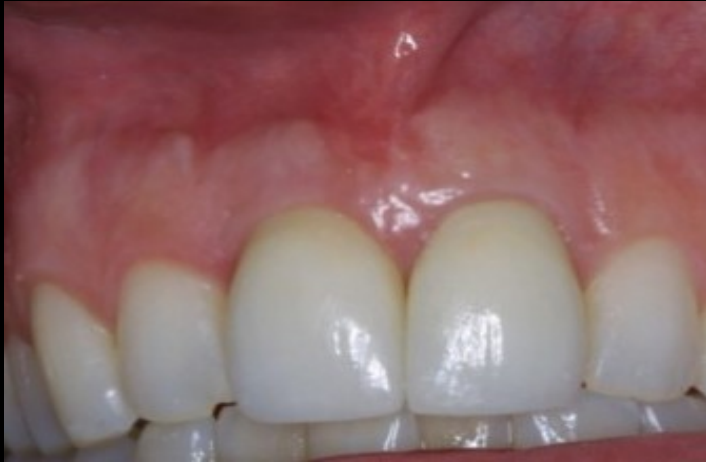INTRA ORAL APPLIANCE



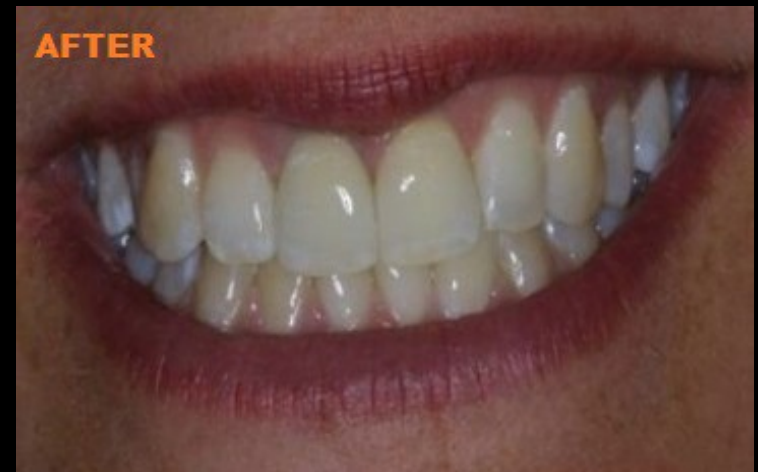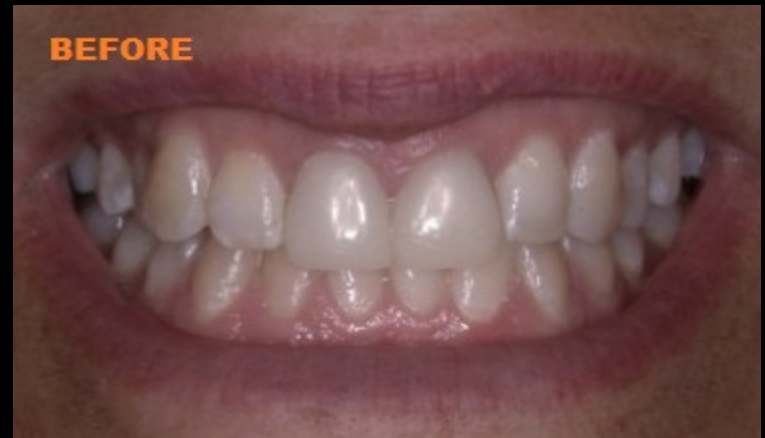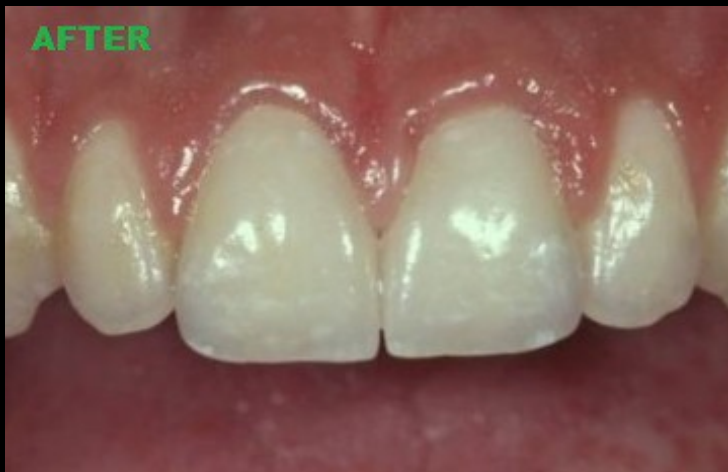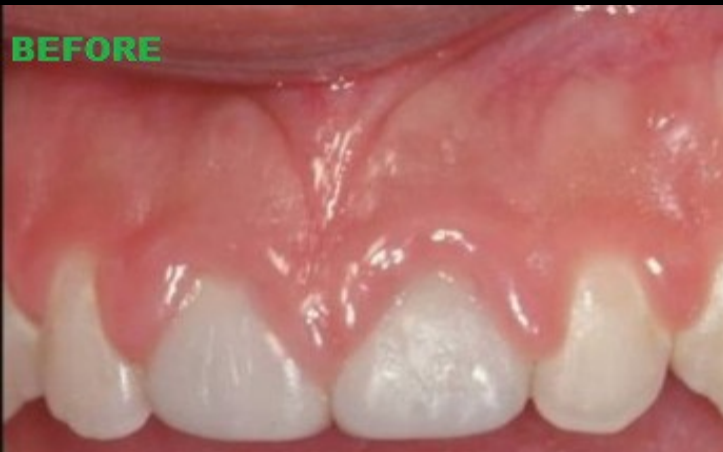Implant over FULL denture



IMPLANT VS ROOT CANAL (RESTORATION)

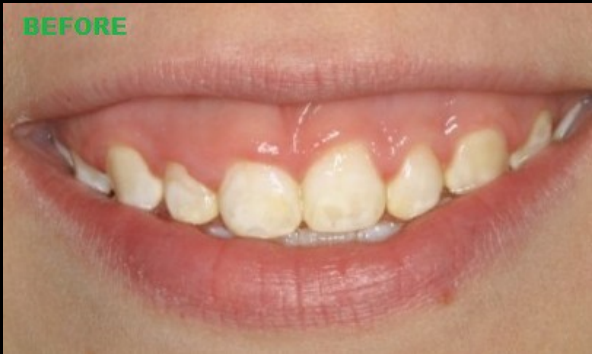

Crown lengthening

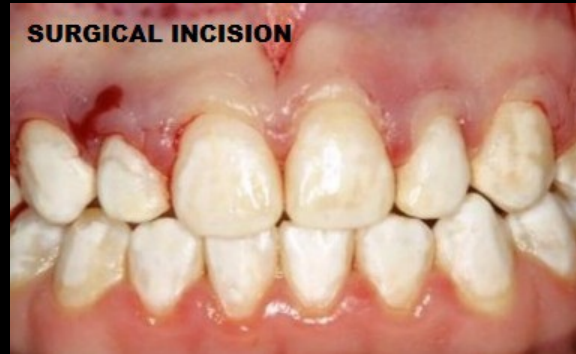

Crown lengthening (SURGICAL PROCEDURE)

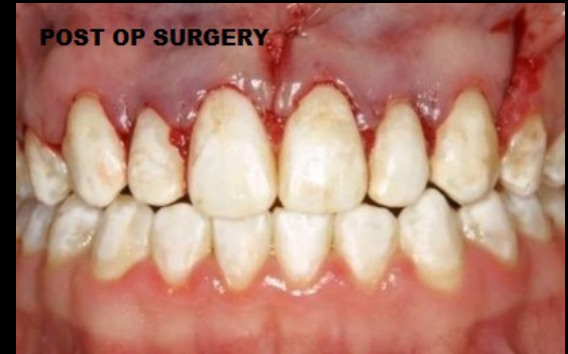BEFORE



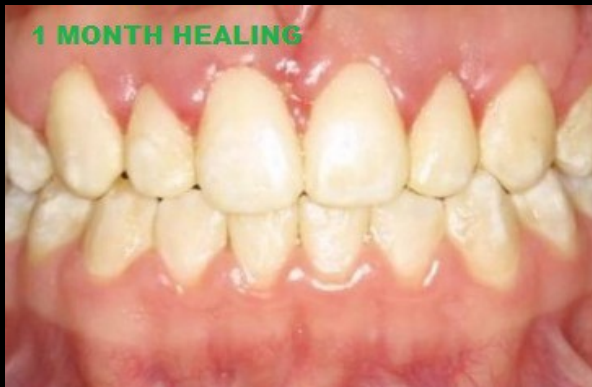SURGICAL INCISION



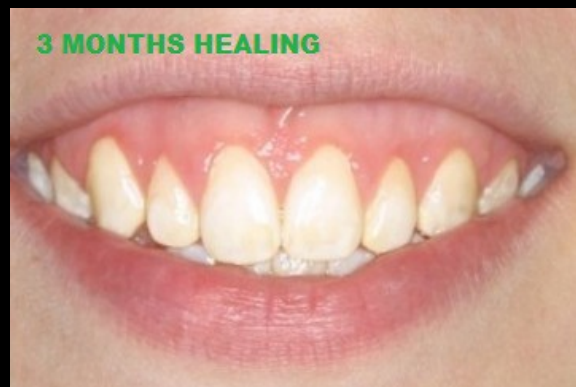POST OP SURGERY



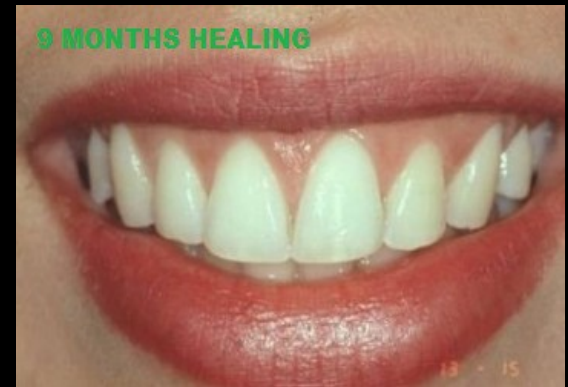1 MONTH HEALING



3 MONTHS HEALING

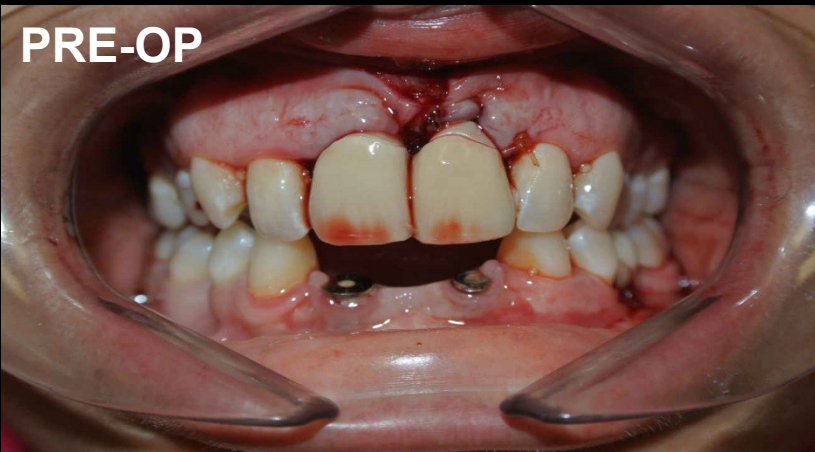


9 MONTHS HEALING

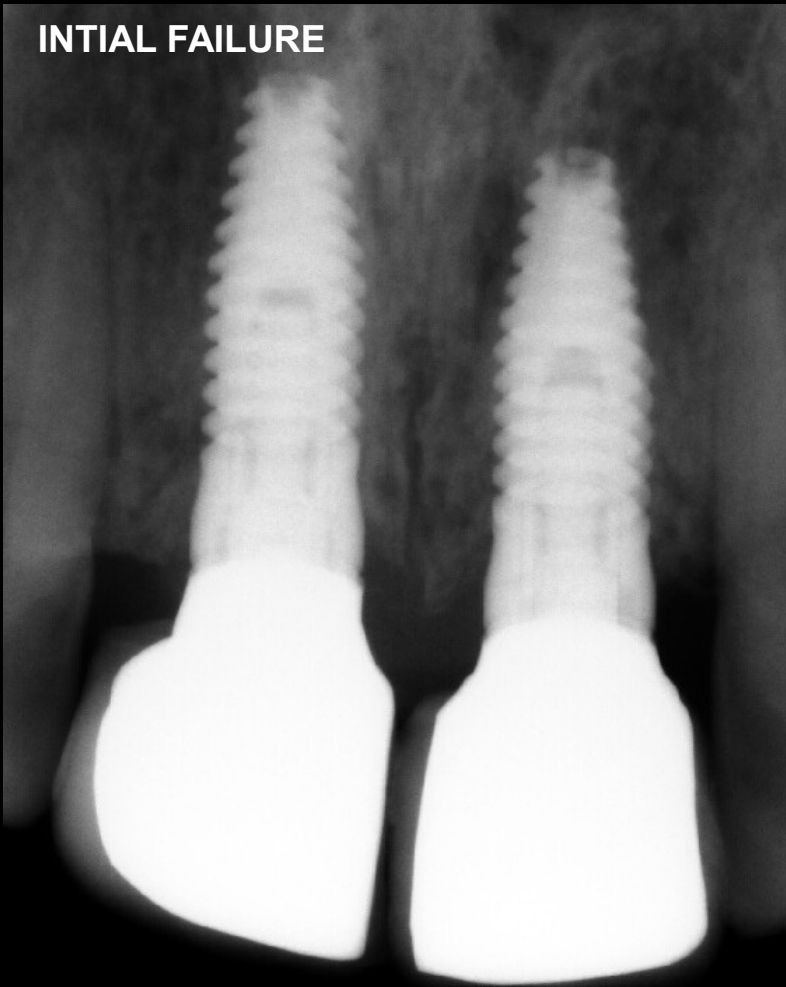


PERI-IMPLANTITIS (BONE GRAFTING REPAIR)

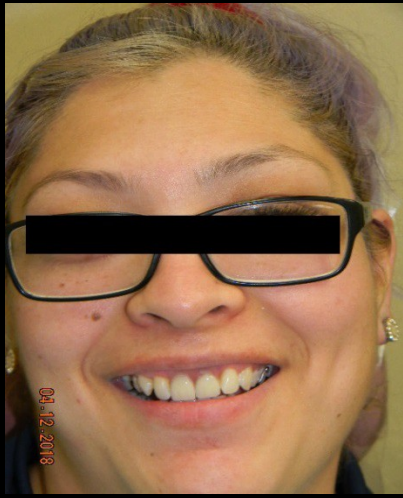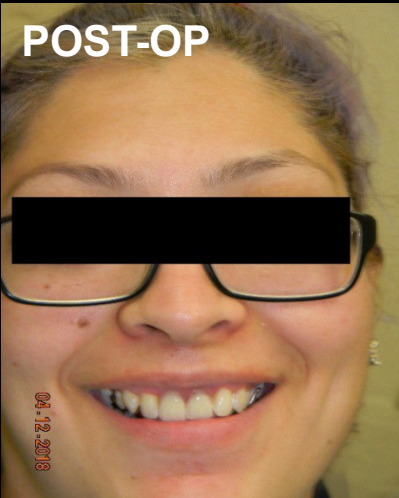PRE-OP



INITIAL FAILURE

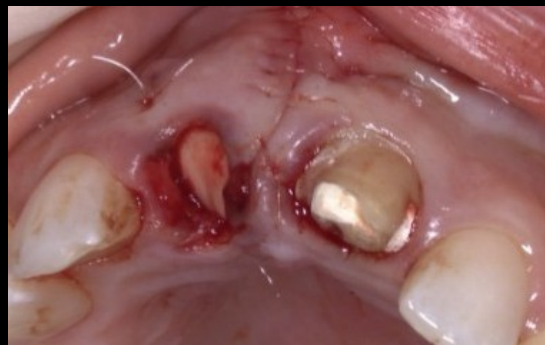
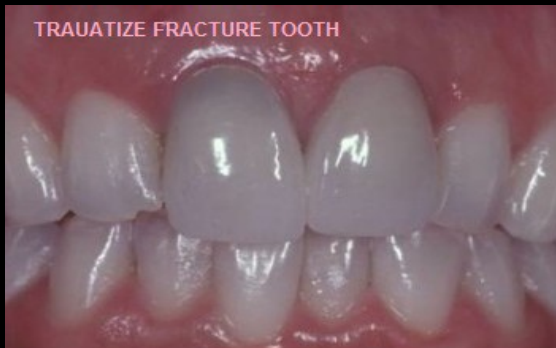
POST-OP

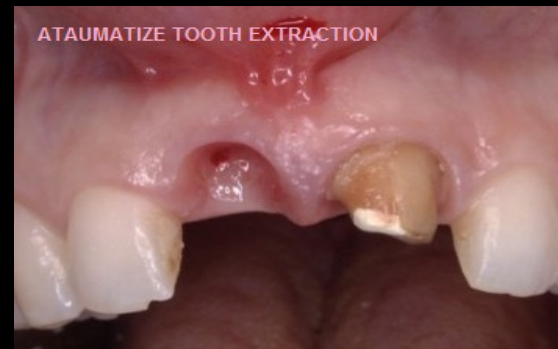

IMPANT REPLACING TRAUMATIZED TOOTH

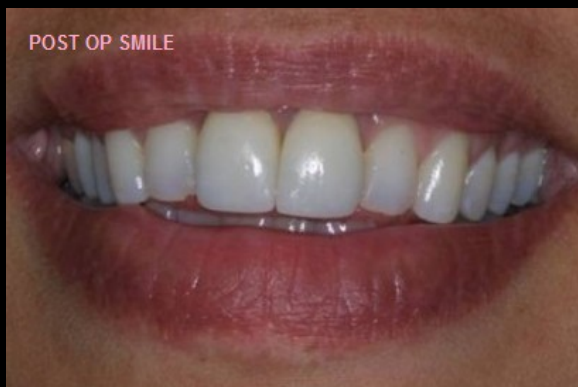TRAUATIZE FRACTURE TOOTH



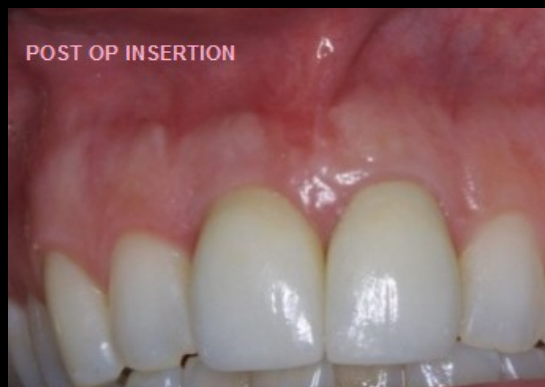ATAUMATIZE TOOTH EXTRACTION



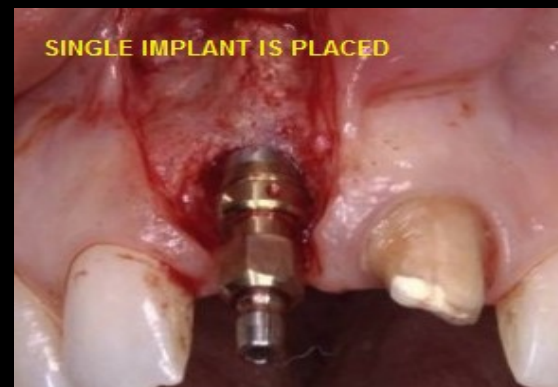
POST OP SMILE



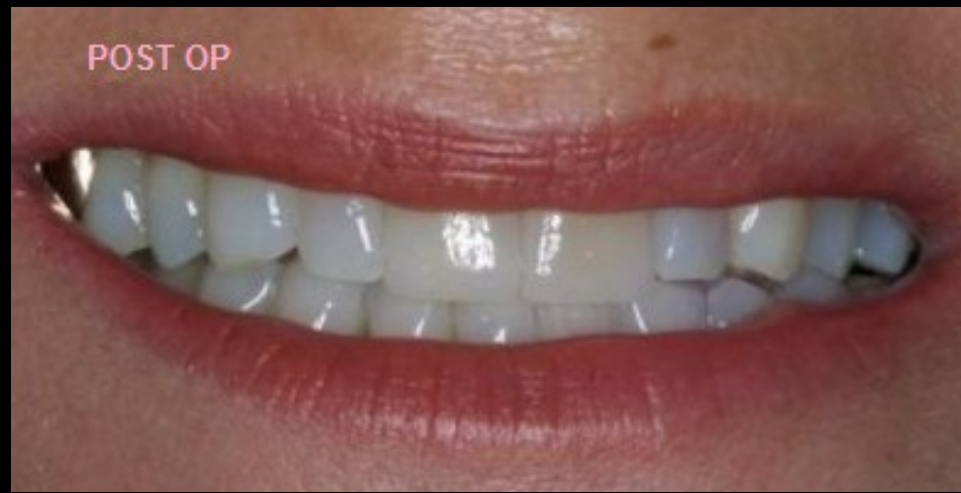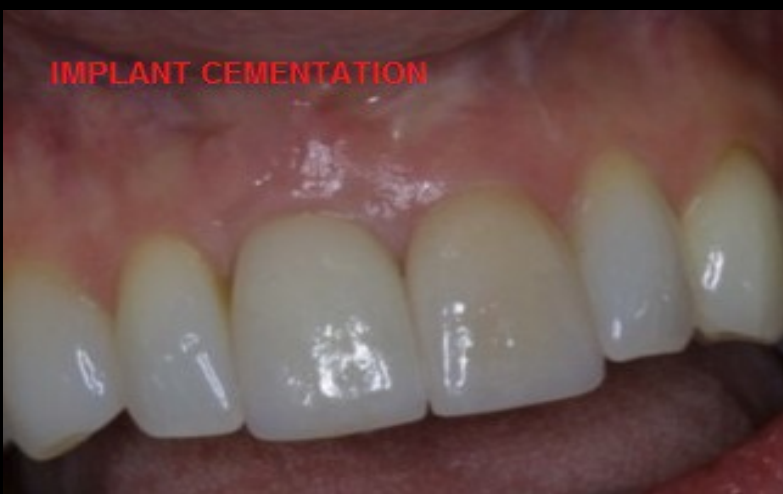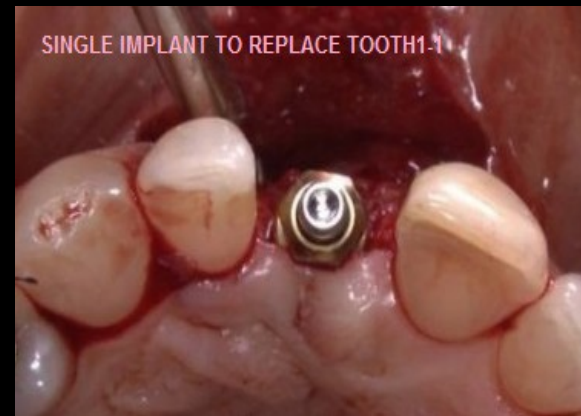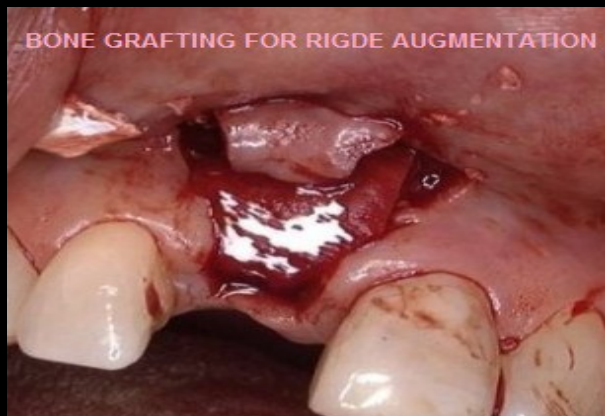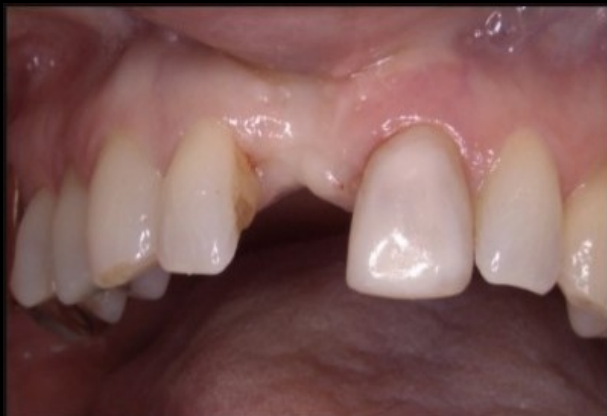POST OP INSERTION



SINGLE IMPLANT IS PLACED

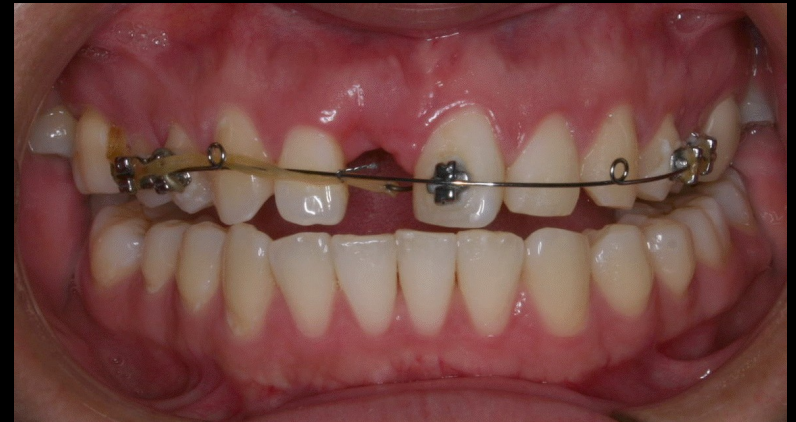
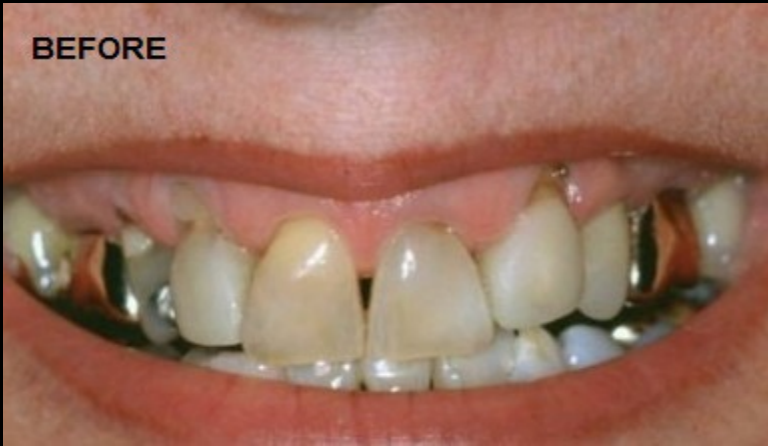

IMPLANT RIDGE AUGMENTATION

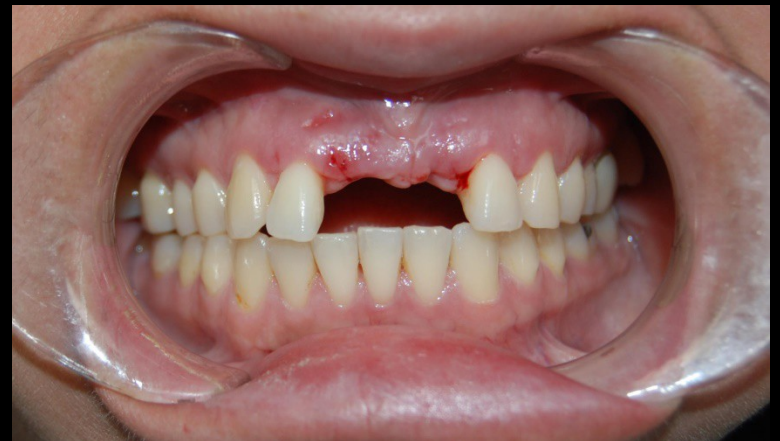
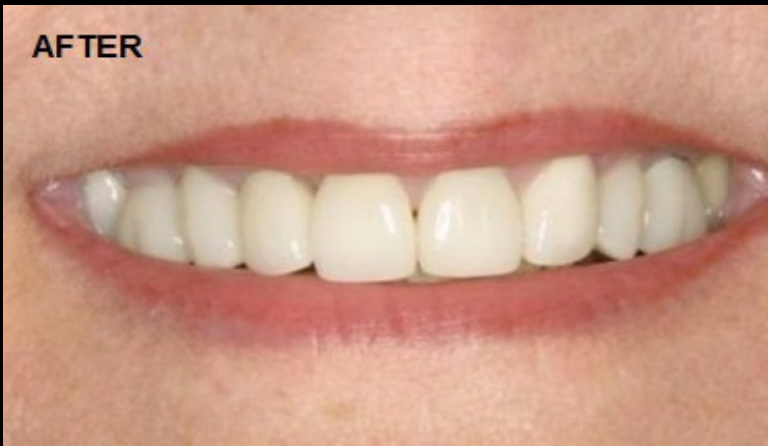
FULL MOUTH REHAB & RIDGE AUGMENTATION

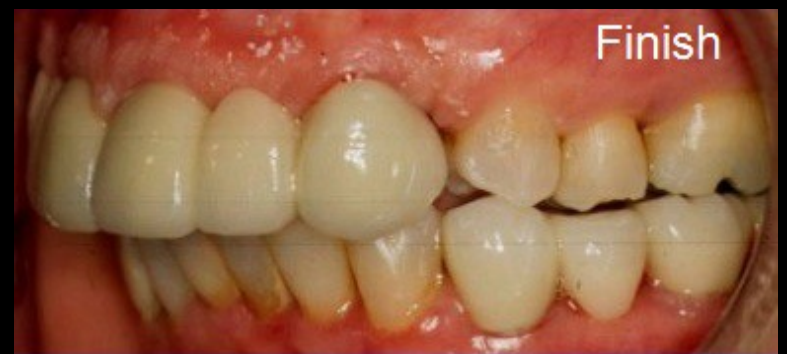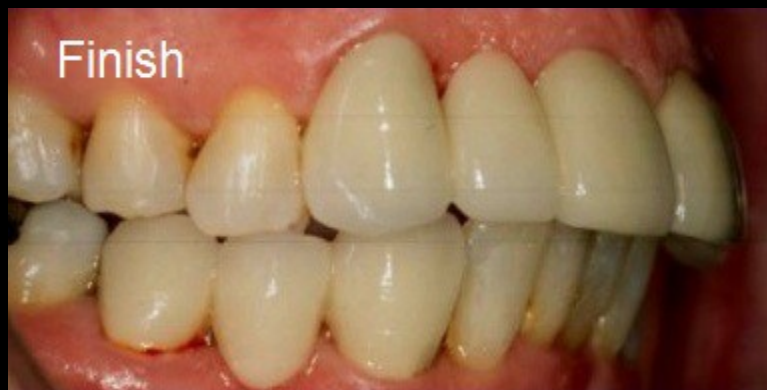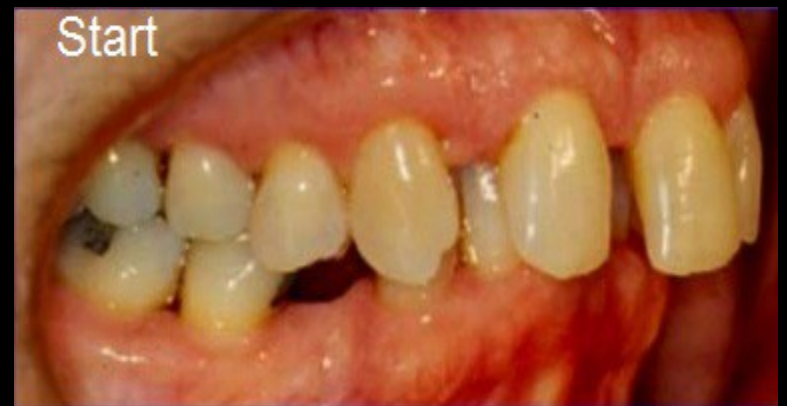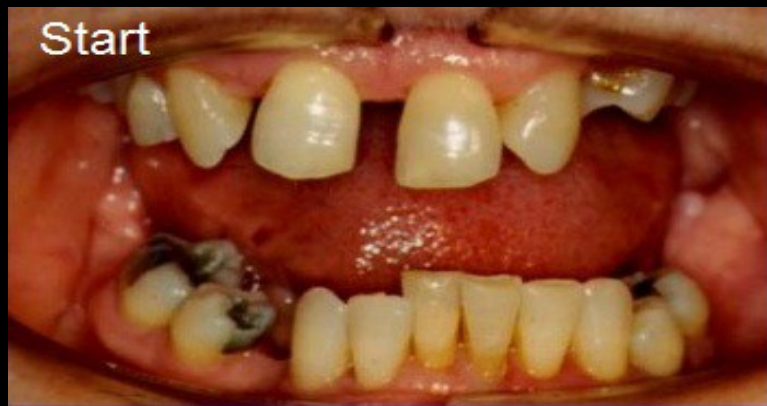BEFORE



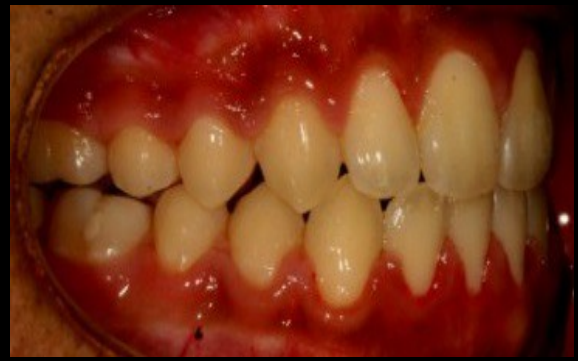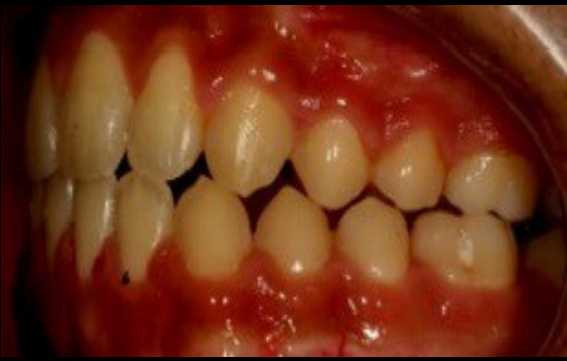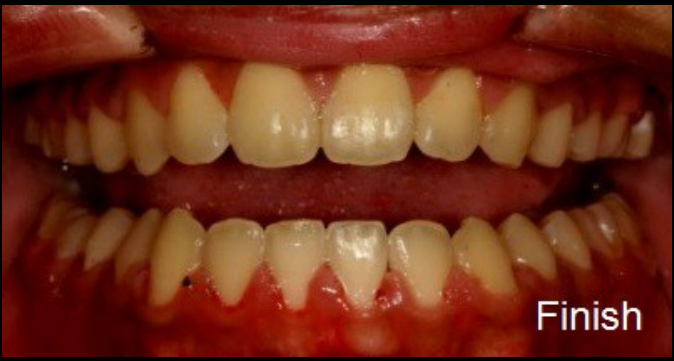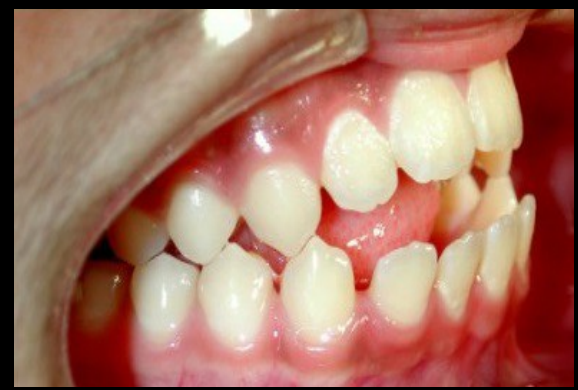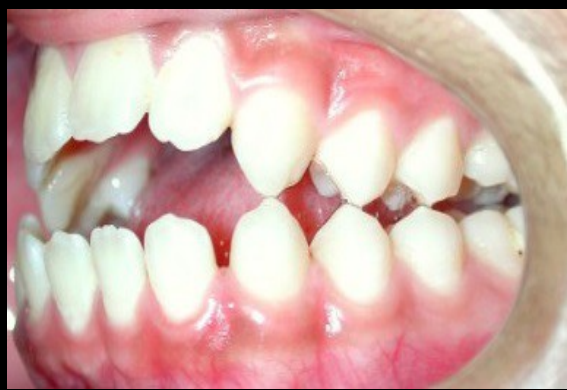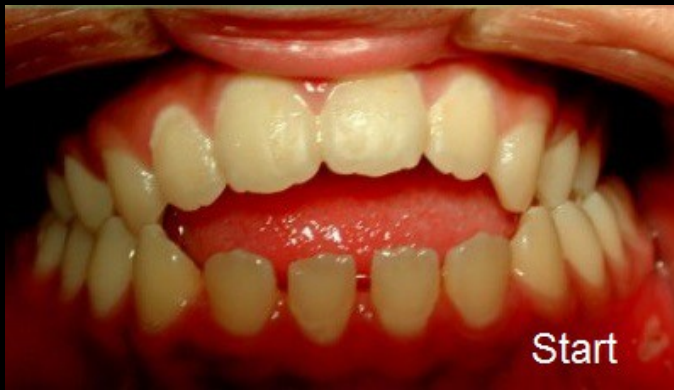AFTER



**58 YEARS OLD FEMALE FULL
ORAL REHABILITAION**

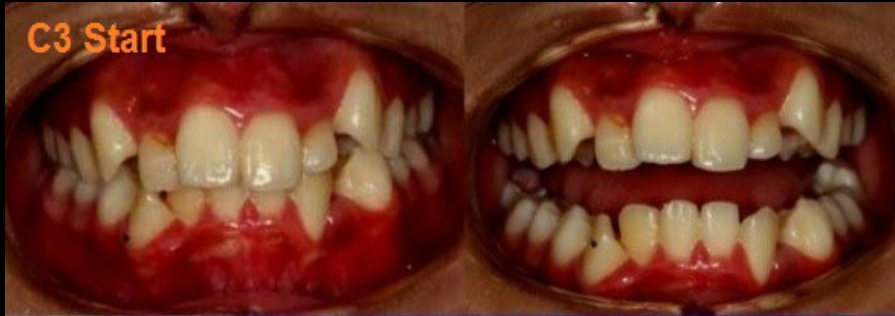

PHASE II ORTHODONTIC (15 YEARS OLD OPEN BITE)

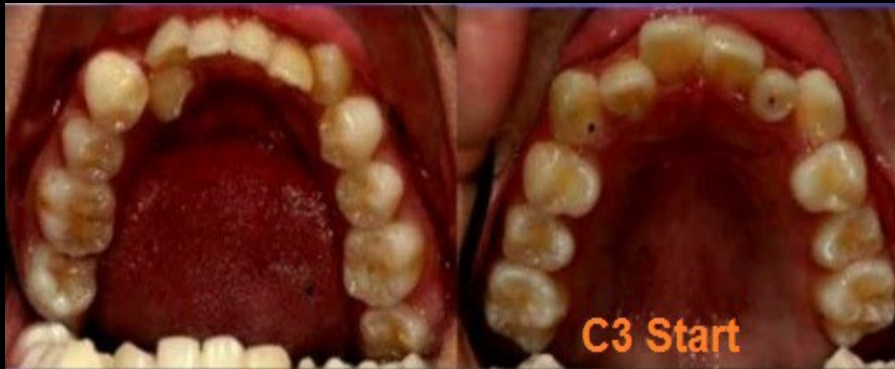
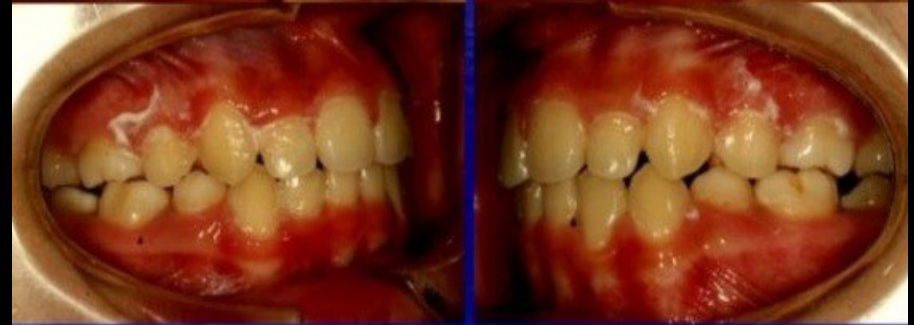
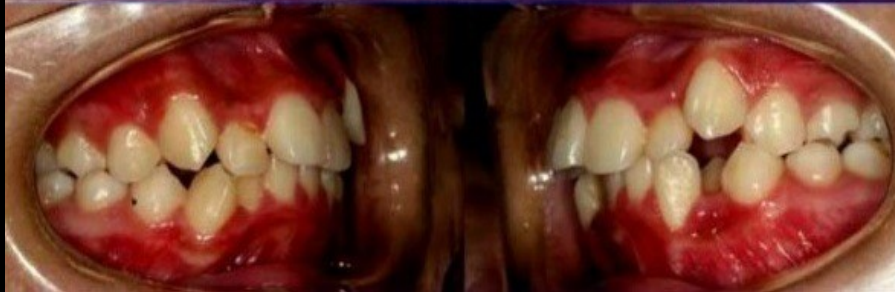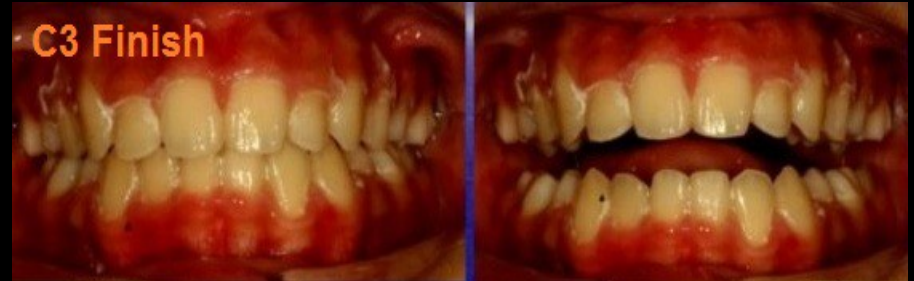ADULT SEVERE CROWDING

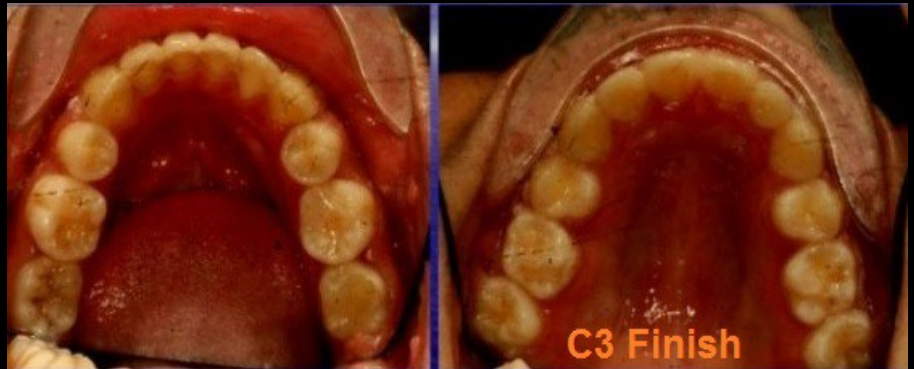C3 Start



C3 Finish



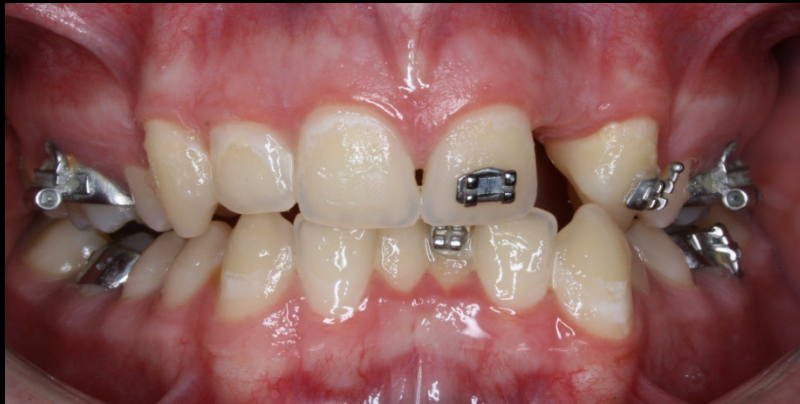C3 Start



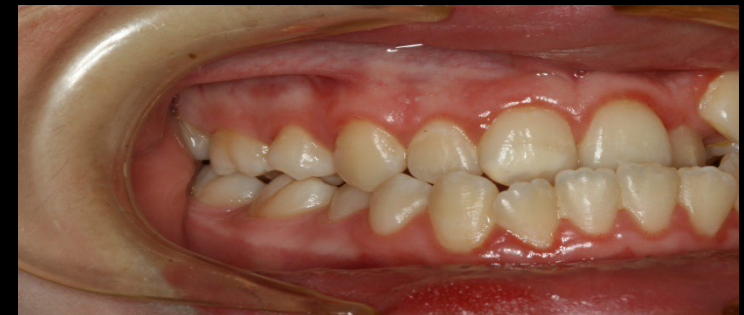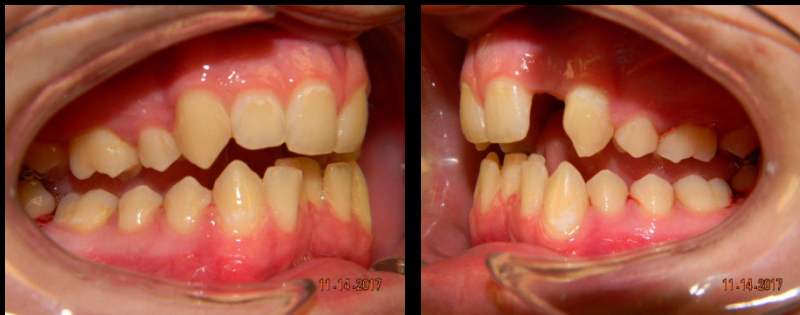
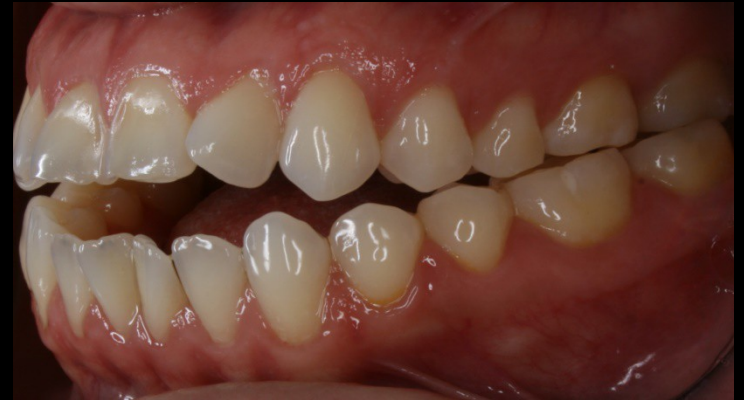C3 Finish

T.M.D

FUNCTIONAL SHIFT

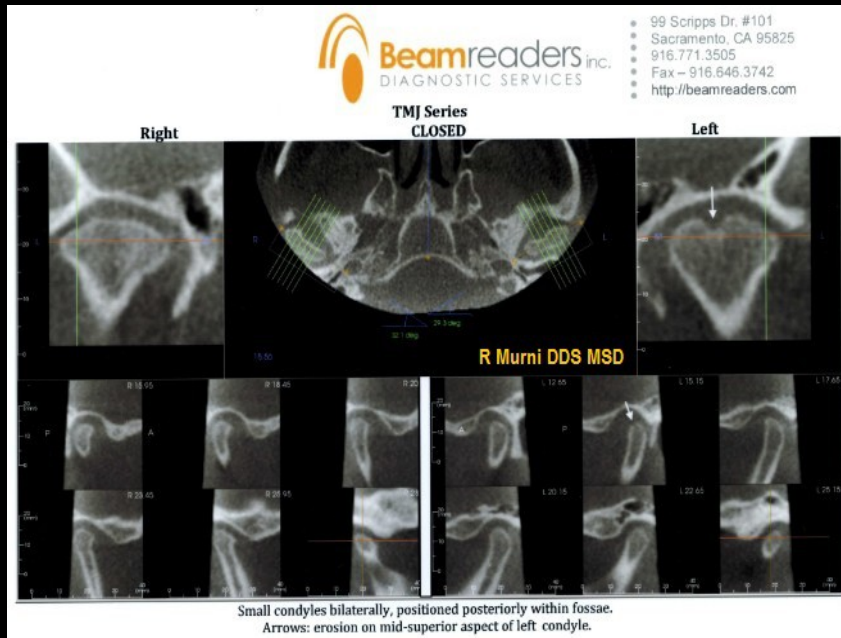


UNILATERAL CROSS BITE



T.M.D

CT SCAN



SPLINT THERAPHY

